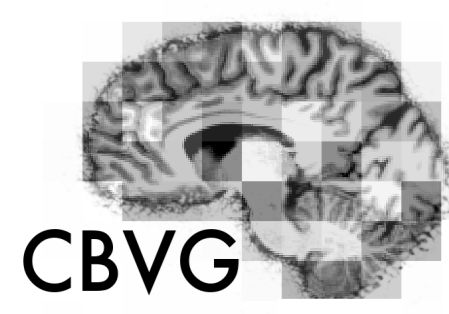

http://vision.bilkent.edu.tr



Structural and Functional Analysis of Patients with Congenital Mirror Movement Disorder

Huseyin Boyaci⁽¹⁾, Aslihan Ors^(1,3), Pinar Boyaci⁽⁴⁾, Tayfun Ozcelik⁽²⁾, Hilmi Uysal⁽⁵⁾, Katja Doerschner⁽¹⁾

(1) Dept. of Psychology, (2) Dept. of Mol. Biol. and Genet., Bilkent Univ., Ankara, Turkey; (3) Dept. of Mol. Biol. and Genet., Bilecik Univ., Bilecik, Turkey; (4) Dokuz Eylul Univ., Izmir, Turkey; (5) Akdeniz Univ., Antalya, Turkey



SfN 2011 Washington, DC

Introduction

Mirror movements are involuntary, non-suppressible movements of one side of the body upon the intentional movements of the homologous muscle groups on the opposite side. Congenital mirror movement disorder (MMD) persists throughout life without mitigation and with no effective treatment. Several hypotheses have been proposed to explain the mechanisms underlying this neurodevelopmental condition. One hypothesis put forward to explain mirror movements proposes an abnormal ipsilateral corticospinal pathway in which unilateral activity of the primary motor cortex leads to bilateral muscle activity [1]. An alternative proposal suggests that bilateral activation of the primary motor cortex due to abnormal interhemispheric inhibition might lead to mirroring in the muscles [2]. Here we report the cases of two siblings with congenital MMD showing pronounced mirror movement in distal upper -, and none in the lower limbs. Using voxel-based morphometry we assessed cortical thickness, mean curvature, surface area and cortical volume. We further measured cortical activity (fMRI) while patients were engaged in cued and uncued motor tasks and compared their cortical and subcortical response patterns to those of healthy controls. We confirm previous qualitative results of bilateral activity in M1, and quantify this effect using a functional ROI approach. Furthermore, we show that for uncued tasks the observed bilateral M1 activity in MMD patients reduces.

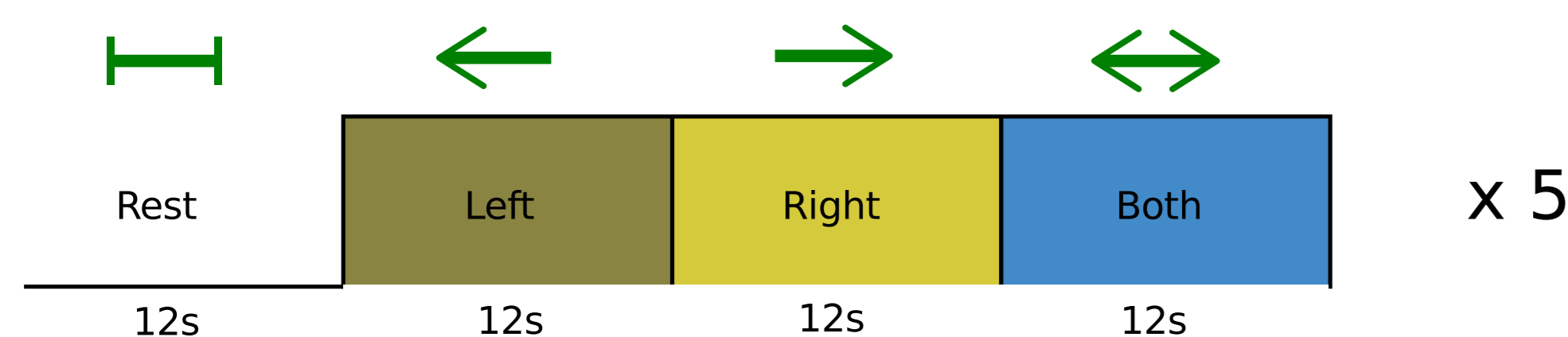
Material and Methods

Participants: 2 right-handed patients (male siblings) with no other abnormalities; Controls Morphometry: 9 age and sex matched healthy participants; Controls fMRI: 2 age, sex and socio-economically matched healthy participants

Tasks during functional scans: Participants were instructed to either rest, move their left, right, or both extremities (fingers, hands, toes) alternating in 12 s blocks. An additional finger-thumb opposition task performed on participants' own pace. Each block was repeated 5 times in each scan.

1. Cued tasks: During each experimental block, arrows indicating which hand (toe etc) to move were displayed at random intervals (min 500ms to max 2500ms) for 250ms

2. Uncued tasks: With the start of each block an arrow was displayed at three random intervals and participants were asked to continue the "rhythm" until the end of the block



MRI acquisition:

Scanner: Siemens 3T Magnetom trio with a twelve-channel phase-array head coil
Structural: T1-weighted three-dimensional (3D) anatomical-volume scan (single-shot turbo flash; voxel size = 1 x 1 x 1 mm³; repetition time, TR = 2600 ms; echo time, TE = 3.02 ms; flip angle = 8 degrees; field of view, FOV = 256 x 224 mm²; slice orientation = sagittal; phase encode direction = anterior-posterior; number of slices = 176; acceleration factor (GRAPPA) = 2)

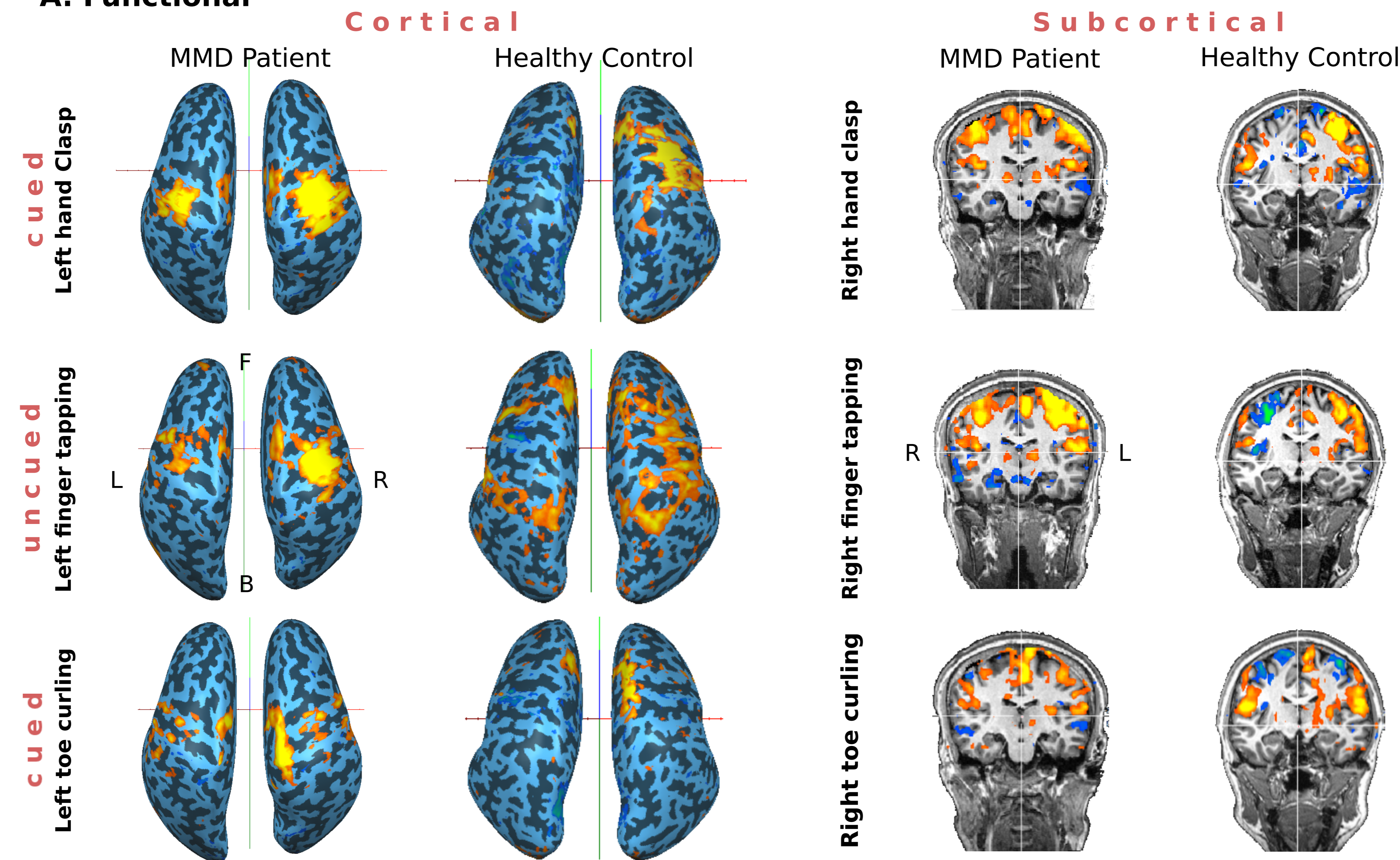
Functional: Echo-planar imaging (EPI) sequence (voxel size = 3 x 3 x 3 mm³; TR = 2000 ms; TE = 40 ms; flip angle = 71 degrees; FOV = 192 x 192 mm²; slice orientation = parallel to calcarine sulcus; phase encode direction = anterior-posterior; number of slices = 26; matrix = 64 x 64).

Experimental software: Java programming platform (<http://bilkent.edu.tr/~hboyaci/PsychWithJava>).

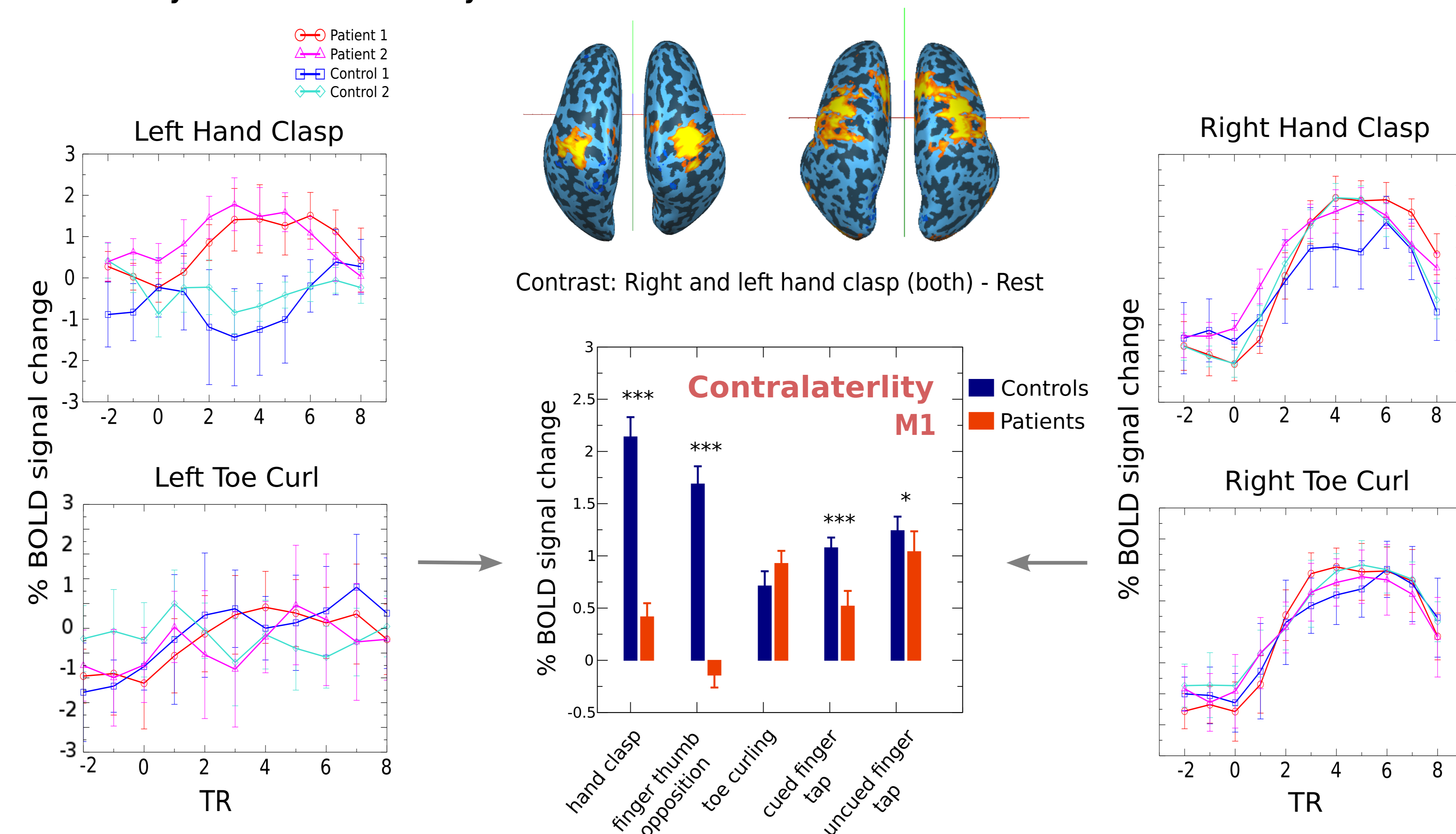
Analysis Tools: Morphometry: Freesurfer; fMRI: Brainvoyager QX

Results

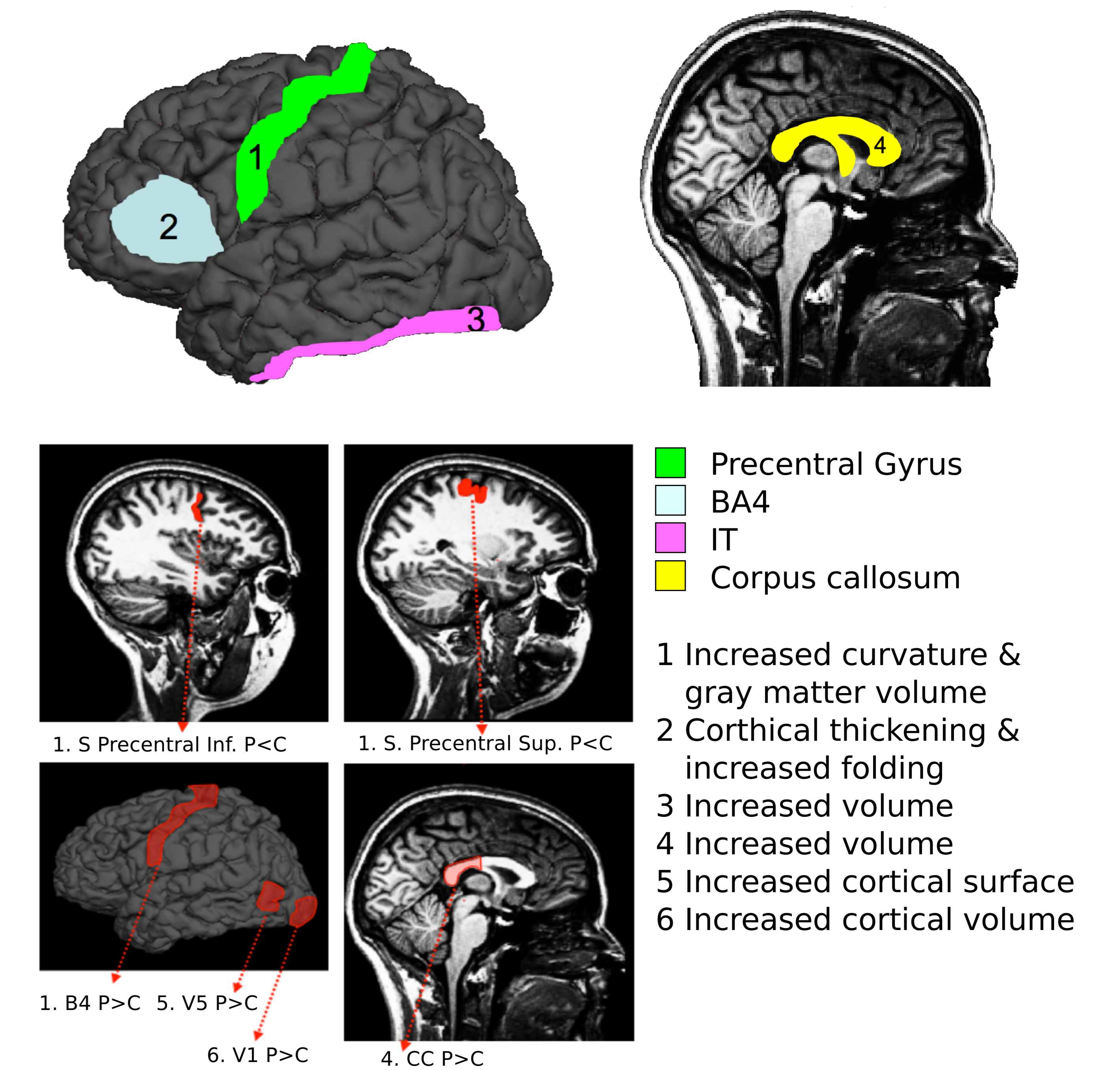
A. Functional



B. ROI analysis & Contralaterality Measure



C. Voxel-based Morphometry



Discussion

The bilateral activity over the primary motor cortex (and thalamus) upon unilaterally intended movements supports the hypothesis that suggests defective interhemispheric interactions could be the reason for the MMD. Our finding that the corpus callosum volume is different in the patients and the controls also supports this hypothesis considering the role of the corpus callosum in interhemispheric interaction.

Acknowledgements

HB and KD were supported by FP7 Marie Curie International Reintegration Grants 239467 and 239494, respectively and by Turkish Scientific and Technological Research Council (TUBITAK) Grant 108K398 and 108S355. Support from the latter grant was also received by AO and TO. HB was also supported by a GEBIP TUBA fellowship.

References

- Cincotta M., Ziemann U. (2008) Neurophysiology of unimanual motor control and mirror movements Clin Neurophysiol, 119(4): 744-62M.
- Leinsinger GL., Heiss DT., Jassoy AG., Pfluger T., Hahn K., Danek A. (1997) Persistent mirror movements: functional MR imaging of the hand motor cortex Radiology, 203(2): 545-52

